

FDG-PET Findings in Patients With Suspected Encephalitis

Bruce Y. Lee, MD,* Andrew B. Newberg, MD,* David S. Liebeskind, MD,† Justin Kung, MD,* and Abass Alavi, MD*

Purpose: Fluorine-18 fluorodeoxyglucose positron emission tomography (FDG-PET) may be used to establish a diagnosis of encephalitis, yet prior descriptions are mainly limited to small case reports. We explore the role of FDG-PET in the diagnostic evaluation of encephalitis.

Methods: Brain FDG-PET was acquired in a consecutive case series of 10 cases of suspected encephalitis over a 5-year-period. Cases with positive Lyme serology were excluded. Two expert reviewers graded the FDG-PET studies in blinded fashion with respect to the clinical history. Retrospective review of the clinical history and examination, laboratory findings, electroencephalogram (EEG), and magnetic resonance imaging (MRI) studies was performed. A diagnosis of encephalitis was based on a combination of the clinical and diagnostic examination findings in each case.

Results: Encephalitis was diagnosed in 6 of 10 cases. FDG-PET hypermetabolism was demonstrated in 5 cases of encephalitis, most frequently involving the medial temporal lobes. Multifocal hypometabolism was noted in at least 2 regions in all 6 cases of encephalitis, with at least 4 regions of hypometabolism noted in 5 of 6 cases. Nonencephalitis cases revealed hypermetabolism in only 1 of 4 cases, ascribed to status epilepticus. Hypometabolism was evident in all nonencephalitis cases.

Conclusion: Encephalitis frequently manifests as FDG-PET hypermetabolism, but focal hypometabolism can also be observed. Seizure activity must be excluded as a possible cause of hypermetabolism in patients suspected of having encephalitis. Because other conditions that can cause hypometabolism may mimic encephalitis clinically, FDG-PET is more likely to serve as an adjunct to lumbar puncture, EEG, and clinical findings rather than a primary diagnostic tool in the management of patients suspected of having encephalitis.

Key Words: encephalitis, positron emission tomography, cognitive impairment, cerebral metabolism

(*Clin Nucl Med* 2004;29: 620–625)

Received for publication January 23, 2004; accepted May 21, 2004.

From the *Division of Nuclear Medicine, Department of Radiology, and the †Department of Neurology and Radiology, Hospital of the University of Pennsylvania, Philadelphia, Pennsylvania.

Reprints: Andrew B. Newberg, MD, Division of Nuclear Medicine, 110 Donner Building, Hospital of the University of Pennsylvania, 3400 Spruce Street, Philadelphia, PA 19104. E-mail: newberg@rad.upenn.edu.

Copyright © 2004 by Lippincott Williams & Wilkins

ISSN: 0363-9762/04/2910-0620

The potential role of fluorine-18 fluorodeoxyglucose positron emission tomography (FDG-PET) in the diagnosis of encephalitis, an acute inflammatory process of the brain with infectious and noninfectious causes, has not yet been fully established. Brain biopsy is the definitive test, but its invasiveness makes it a last resort. Unless contraindicated, suspected patients usually undergo lumbar puncture (LP) initially. Standard cerebrospinal fluid (CSF) analysis along with testing for specific infectious agents can provide important clues. However, typical CSF findings for encephalitis (a moderately elevated white blood cell count with mononuclear cell predominance, normal or elevated protein levels, and normal glucose levels) may also be seen in aseptic meningitis.

Anatomic imaging, such as magnetic resonance imaging (MRI) and computed tomography (CT), is relatively nonspecific.^{1–3} Although structural imaging studies may reveal lesions that either cause or are associated with encephalitis, normal studies may also be noted. Similarly, the presence of abnormal electroencephalography (EEG) is an important clue, but lack of abnormalities can be common.^{4–8}

The clinical signs and symptoms of encephalitis are nonspecific, ranging from vague constitutional symptoms to confusion or coma. The initial neurologic deficits may be mild or severe, focal or generalized, stable or progressive, and persistent or transient. Acute encephalitis may elicit almost any neurologic deficit, seizures, increased intracranial pressure, respiratory decompensation, or inappropriate antidiuretic hormone secretion. Although full recovery is possible, a gamut of permanent intellectual, motor, psychiatric, visual, and auditory defects may result. Death can also occur.^{5,9}

When patients present with the types of symptoms described here, the differential diagnosis includes meningitis, brain abscess, subdural empyema, brain tumor, subarachnoid hemorrhage, subdural hematoma, and traumatic intracranial hemorrhage.^{3,5,10} The difficulty of making a clear diagnosis, along with the benefits of early detection and treatment, and morbidity associated with brain biopsy (the current gold standard test) all provide significant opportunity for exploring minimally invasive tests that may facilitate the diagnosis. The ability of FDG-PET to detect even mild inflammation has been well established and makes FDG-PET a potential candidate to fill such a role.^{11,12} The literature on the use of

FDG-PET in encephalitis has been largely limited to case reports and very small case series. We retrospectively reviewed our experience with FDG-PET in the diagnosis of encephalitis and its correlation to the other diagnostic tests and the clinical presentation and course.

METHODS

As we previously reported on our experience with Lyme encephalitis, all cases of Lyme disease were excluded.¹³ From August 1998 to January 2003, a total of 10 patients without positive Lyme serologies (5 men and 5 women) received brain FDG-PET to evaluate for the presence of encephalitis. Ages ranged from 17 to 78 (mean age, 47 years). In all cases, FDG (average dose 7.16 mCi) was administered intravenously approximately 40 minutes before scanning. Scans were obtained over 40 minutes in a HEAD PENN PET dedicated brain scanner. The scanner had a field of view of 25.6 cm, data were reconstructed using a 3-dimensional reconstruction algorithm into an image matrix of 128 × 128, and the maximal spatial resolution at full width at half maximum (FWHM) was approximately 4 mm. The images were acquired according to previously described methods and reconstructed using a Weiner filter and Chang first-order attenuation correction in axial, coronal, and sagittal planes.¹⁴

Retrospective review of the clinical features, laboratory results, EEG, and MRI was conducted independently of the FDG-PET analyses. For review of the FDG-PET scans, the brain was divided into 20 regions: right and left frontal lobes, right and left parietal lobes, right and left occipital lobes, right and left basal ganglia, right and left cerebella, right and left sensorimotor regions, right and left medial temporal lobes, and right and left lateral temporal lobes. For each region, 2 expert readers assessed the amount of metabolic activity using the following graded scale.

- 7 = Significantly increased
- 6 = Moderately increased
- 5 = Mildly increased
- 4 = Normal
- 3 = Mildly decreased
- 2 = Moderately decreased
- 1 = Severely decreased
- 0 = No activity

This subjective analysis was used for several reasons. Encephalitis findings do not frequently conform to the normal structural contours of the brain and therefore, it is more difficult to apply templates or automated regions of interest. Furthermore, the small sample size required a more qualitative analysis to make comparisons across the group of patients. Finally, other approaches such as statistical parametric mapping and region-of-interest analysis are not typically used in routine clinical practice and require more consistent findings than those observed in encephalitis.

FDG-PET correlation with clinical features was subsequently performed. A clinical diagnosis of encephalitis was based on a combination of patient history, symptoms, physical examination findings, CSF findings, EEG, and response to therapy.

RESULTS

None of the patients had positive serologies for herpes simplex virus (HSV) or varicella zoster virus (VZV). None of the patients demonstrated overt seizure activity immediately before, during, or after the FDG-PET scans.

Patients Diagnosed With Encephalitis

Overall, 6 of the 10 patients had a discharge diagnosis of encephalitis. Their clinical findings are summarized in Table 1 and their FDG-PET scores are listed in Table 2. Five underwent LP and 4 had elevated WBC counts on CSF analysis. One patient with advanced acquired immune deficiency syndrome (AIDS) did not receive an LP because it was decided that a more definitive diagnosis of encephalitis would not have changed clinical management. None of the patients diagnosed with encephalitis had normal FDG-PET scans. Five of the 6 patients had increased radiopharmaceutical uptake in at least 1 of the 19 regions analyzed (see Figs. 1 and 2). The most frequently affected regions were the medial temporal lobes (5 of the patients). Two patients had increased activity in the left lateral cerebellar lobes and 1 patient in the vermis. All 6 patients had decreased activity in at least 2 regions. Five had decreased radiopharmaceutical uptake in at least 4 regions. Hypometabolism was most common in the frontal and parietal lobes.

Patients Not Diagnosed With Encephalitis

Table 3 shows the clinical findings for the 4 remaining patients not clinically diagnosed with encephalitis. One was discharged with a diagnosis of lupus encephalopathy, another subacute cognitive decline, and a third diffuse degenerative disease. Patient no. 4 was eventually diagnosed as having status epilepticus and was subsequently treated for seizures with complete neurologic recovery. Table 4 summarizes the PET scores for this group. None of the cases had normal

TABLE 1. Clinical Findings of Encephalitis Cases

Patient no.	Age (yrs)	Sex	WBC	Protein	Glucose	FDG
1	61	M	1	43	62	7.98
2	60	M	81	93	68	7.77
6	44	F	42			10.17
7	78	F	80			4
9	34	M	0			1.98
10	17	F	1	32	84	1.78

TABLE 2. FDG-PET Scores for Cases of Encephalitis*

Patient no.	Frontal		Parietal		Medial temporal		Lateral temporal		Occipital		Sensorimotor		Basal ganglia		Cerebellum		Thalamus		Vermis	
	R	L	R	L	R	L	R	L	R	L	R	L	R	L	R	L	R	L		
1	0	1	3		2		3	5			2	3	3	3	3	3	3	3		
2	2	2	3	3	5	7	3	3	3	3	3	3					3	3	5	
6			3	3		7		5					7							
7	3	3	2	2	3	5	3	3												
9						1		3								3				
10	3	3	3	3	5	3	3	3	3	3	3	3			3	3	3	3		

*Normal regions are blank.

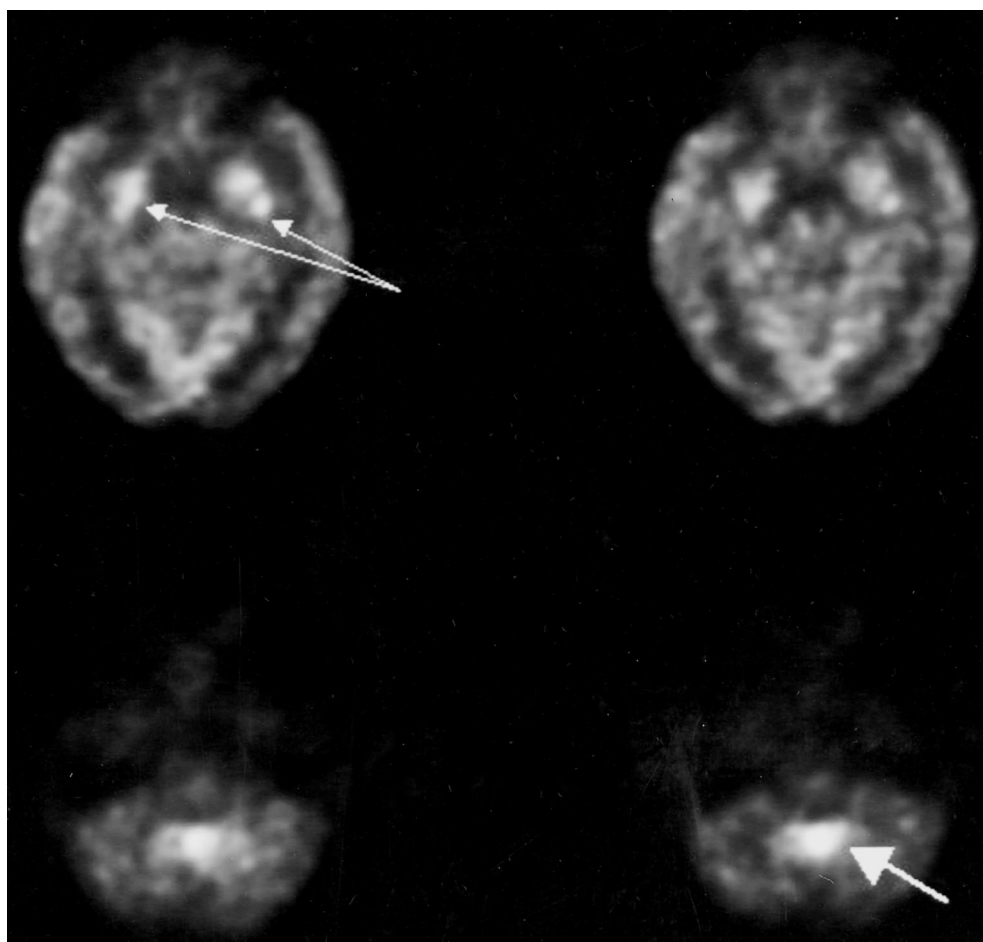


FIGURE 1. Transaxial FDG-PET scan images of a 60-year-old man with encephalitis demonstrating areas of substantially increased metabolism in the medial temporal lobes (small arrows) and the vermis (large arrow). Other cortical areas had mildly to moderately decreased metabolism.

FDG-PET scans. Of the group of patients without encephalitis, only the fourth case (status epilepticus) demonstrated FDG-PET hypermetabolism. All 4 cases without encephalitis had decreased radiotracer activity in at least 2 regions (see Fig. 3).

DISCUSSION

There are approximately 11,000 annual reported cases (or 5 cases per 100,000 people) of all forms of encephalitis. Diagnosing encephalitis can be difficult, because the clinical presentation is nonspecific and there is a wide differential

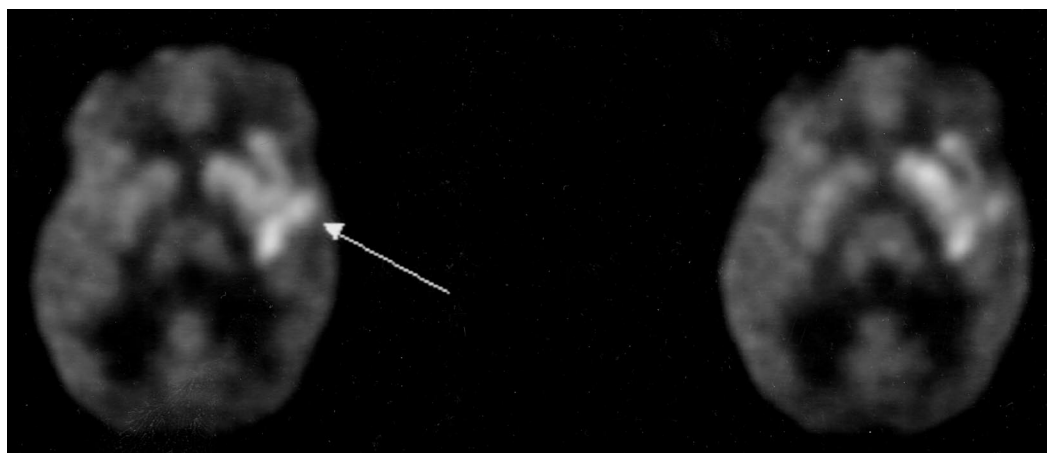


FIGURE 2. FDG-PET scan of a 44-year-old woman with encephalitis demonstrating areas of substantially increased metabolism in the left temporal lobe and left basal ganglia (arrow). The parietal lobes were mildly decreased and the remaining brain structures had relatively normal metabolism.

TABLE 3. Clinical Findings of Nonencephalitis Cases

Patient no.	Age	Sex	WBC	Protein	Glucose	FDG
3	45	F	3	37	60	8.1
4	37	M	9	47	63	10.76
5	44	F	9			14.2
8	62	M	None			3.86

diagnosis associated with the presenting signs and symptoms. The differential diagnoses encompass a diverse spectrum of disorders, requiring various therapeutic interventions that may require emergent application. If herpes simplex (HSV) or varicella zoster encephalitis (VZV) is suspected, administration of antiviral agents such as acyclovir or foscarnet should not be delayed. Although most cases of encephalitis caused by viruses other than HSV or VZV are not treatable, timely supportive care is important.¹⁰

An accurate diagnosis or exclusion of encephalitis is therefore critical. Brain biopsy, although definitive, carries significant risk. A 1991 retrospective study, which included a fatal intracranial hemorrhage, suggests that brain biopsy should not be routinely used to diagnose focal encephalitis.¹⁵

Other diagnostic procedures are far from definitive. A literature search revealed few recent reports on the accuracy of LP, CT, MRI, or EEG in diagnosing encephalitis. CT is relatively insensitive to early changes. Enhanced detection of white matter lesions may be achieved with MRI.¹⁶

Consequently, any test that can aid in the diagnosis of encephalitis could be clinically useful. Additionally, there is a need for a test that can serially monitor the course of encephalitis so that supportive care can be adjusted accord-

ingly. As a relatively noninvasive, low-risk procedure, FDG-PET is a potential candidate to fill these roles.

A majority of the literature on the use of FDG-PET in encephalitis consists of case reports. Kassubek et al. reported 2 cases (a 61-year-old man and a 51-year-old man) of limbic encephalitis in which hypermetabolism was seen in bilateral hippocampal areas on FDG-PET coregistered with 3-dimensional MRI.¹⁷ Kaiboriboon et al. used serial MRIs and FDG-PET scans to follow a 12-year-old patient with pathologically confirmed Rasmussen's encephalitis for 3 years. An FDG-PET scan 6 months after the onset of symptoms was normal. However, although an MRI performed 30 months after symptom onset was normal, an FDG-PET scan at 36 months showed areas of marked hypermetabolism.¹⁸

Fakhoury et al. reported 2 women (ages 33 and 61 years) with paraneoplastic limbic encephalitis who had normal MRIs but FDG-PET scans that showed right hippocampal hypermetabolism. In both cases, the patients presented with seizure activity. Therefore, the authors felt that it could not be determined if the focal hypermetabolism on FDG-PET represented the inflammatory process or subclinical seizure activity.¹⁹

Hirayama et al. described the case of a 3-year girl with respiratory syncytial virus (RSV) encephalitis. FDG-PET demonstrated hypometabolism in the cerebellar cortex, the same location where SPECT imaging showed hypoperfusion and MRI exhibited hyperintensity on T2-weighted imaging. The FDG-PET and SPECT findings remained 1 year after the onset of symptoms, whereas the MRI showed mild cerebellar atrophy.²⁰

Consistent with the prior literature, our series, which represents the largest in the literature to date, suggests that encephalitis generally manifests itself on FDG-PET as areas of hypermetabolism. However, there can also be large areas

TABLE 4. FDG-PET Scores for Cases of Nonencephalitis*

Patient no.	Frontal		Parietal		Medial temporal		Lateral temporal		Occipital		Sensorimotor		Basal ganglia		Cerebellum		Thalamus		
	R	L	R	L	R	L	R	L	R	L	R	L	R	L	R	L	R	L	
3	3	3	3	3	2	3	3				3	3							
4			5	3	3		7		6	3	3			5	6				
5	3	3	3	3			3		3			3	3					3	3
8	3	3	3	3	1	1	3	3										3	3

*Normal regions are blank.

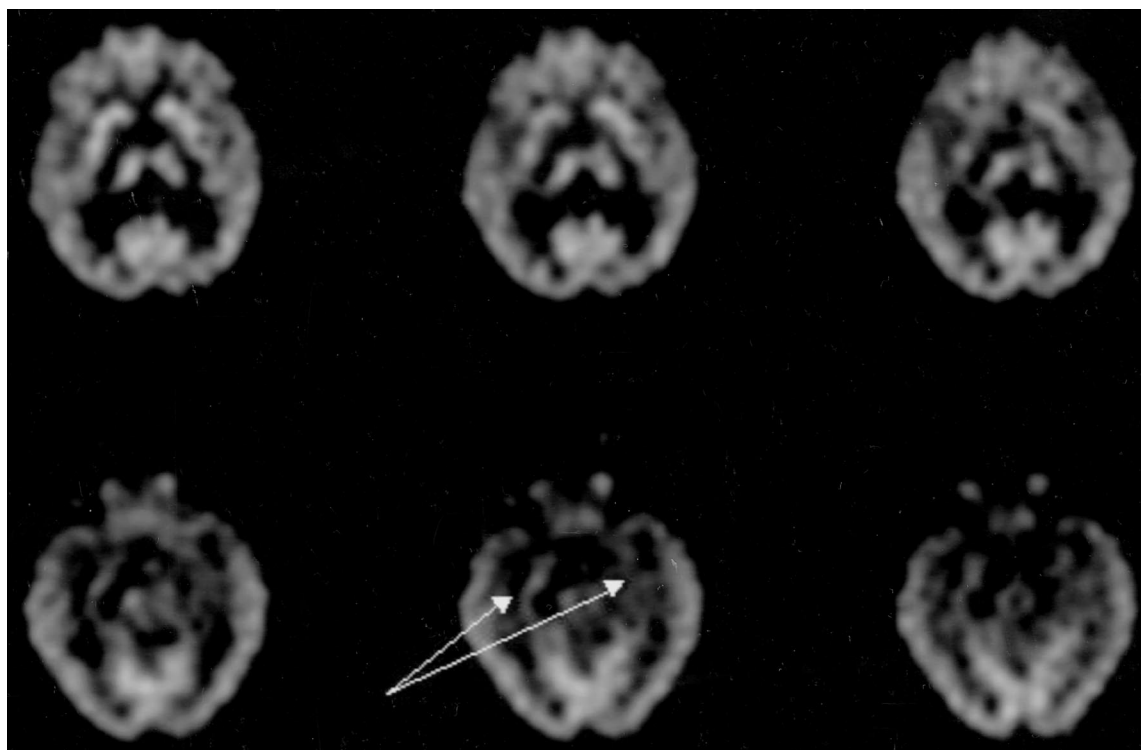


FIGURE 3. FDG-PET scan of a 62-year-old man who was not diagnosed with encephalitis demonstrating areas of mildly decreased metabolism in the frontal and temporal lobes and thalamus with the medial temporal lobes the most affected (arrow).

of hypometabolism associated with encephalitis. Our findings suggest that the hypermetabolism seen on the FDG-PET scans can be the result of active inflammation, but it is necessary to exclude ictal seizure activity as a cause of hypermetabolism. None of the patients had overt seizures immediately associated with the scans. In 2 of the patients, the hypermetabolic areas were so large that clinical signs should have been readily apparent had these areas represented seizure foci. Moreover, 4 of the patients did not demonstrate any seizure activity on EEGs done at separate times from the PET scans. Of course, checking EEGs during the PET scan would be the only way of definitely ruling out subclinical seizure activity as the cause of the hypermetabolism. This in fact was the case for the 1 patient not diagnosed with

encephalitis who did demonstrate significant hypermetabolism on the FDG-PET scan. This patient was subsequently found to be in status epilepticus. This suggests the importance of obtaining EEGs on all patients with hypermetabolism on the FDG-PET scan suspected of encephalitis because this may be the most likely false-positive diagnosis.²¹⁻²⁴ However, if the EEG is negative, then hypermetabolism is most likely associated with the inflammatory process characteristic of encephalitis regardless of the exact etiology.

It remains to be determined how early in the course of encephalitis changes on FDG-PET are seen and how long they persist after symptoms have resolved. In our series, 1 patient had a distant history (greater than 2 years before the FDG-PET scans) of encephalitis and did not appear to have

any residual findings. Future studies with serial FDG-PET scans may help determine the time course of FDG-PET findings.

Our series did not identify any clear FDG-PET characteristics that distinguish encephalitis from conditions such as lupus encephalopathy. There is no evidence that FDG-PET can be used alone to diagnose encephalitis. Therefore, its role is more likely as an adjunct to LP, EEG, and clinical findings.

Larger series will help elucidate how findings correlate with disease activity, how often hypermetabolism represents seizure (subclinical or clinical) activity versus significant inflammation, and how long findings on FDG-PET persist after clinical symptoms and inflammation have abated. A larger cohort may also allow patients to be stratified by causative organisms/agents and presenting symptoms. Perhaps certain organisms and/or presenting symptoms may be associated with greater degrees of inflammation and in turn generate more dramatic FDG-PET findings.

REFERENCES

1. Lizerbram EK, Hesselink JR. Neuroimaging of AIDS. I. Viral infections. *Neuroimag Clin North Am.* 1997;7:261–280.
2. Falcone S, Post MJ. Encephalitis, cerebritis, and brain abscess: pathophysiology and imaging findings. *Neuroimag Clin North Am.* 2000;10:333–353.
3. Wong J, Quint DJ. Imaging of central nervous system infections. *Semin Roentgenol.* 1999;34:123–143.
4. Hinson VK, Tyor WR. Update on viral encephalitis. *Curr Opin Neurol.* 2001;14:369–374.
5. Roos KL. Encephalitis. *Neurol Clin.* 1999;17:813–833.
6. Lai CW, Gragasin ME. Electroencephalography in herpes simplex encephalitis. *J Clin Neurophysiol.* 1988;5:87–103.
7. Markand ON. Electroencephalography in diffuse encephalopathies. *J Clin Neurophysiol.* 1984;1:357–407.
8. Markand ON. Pearls, perils, and pitfalls in the use of the electroencephalogram. *Semin Neurol.* 2003;23:7–46.
9. Gutierrez KM, Prober CG. Encephalitis. Identifying the specific cause is key to effective management. *Postgrad Med.* 1998;103:123–143.
10. Chaudhuri A, Kennedy PG. Diagnosis and treatment of viral encephalitis. *Postgrad Med J.* 2002;78:575–583.
11. Newberg AB, Alavi A. Neuroimaging in patients with head injury. *Semin Nucl Med.* 2003;33:136–147.
12. Zhuang H, Alavi A. 18-fluorodeoxyglucose positron emission tomographic imaging in the detection and monitoring of infection and inflammation. *Semin Nucl Med.* 2002;32:47–59.
13. Newberg A, Hassan A, Alavi A. Cerebral metabolic changes associated with Lyme disease. *Nucl Med Commun.* 2002;23:773–777.
14. Karp JS, Freifelder R, Geagan MJ, et al. Three-dimensional imaging characteristics of the HEAD PENN-PET scanner. *J Nucl Med.* 1997;38:636–643.
15. Anderson NE, Willoughby EW, Synek BJ, et al. Brain biopsy in the management of focal encephalitis. *J Neurol Neurosurg Psychiatry.* 1991;54:1001–1003.
16. Sze G, Zimmerman RD. The magnetic resonance imaging of infections and inflammatory diseases. *Radiol Clin North Am.* 1988;26:839–859.
17. Kassubek J, Juengling FD, Nitzsche EU, et al. Limbic encephalitis investigated by 18FDG-PET and 3D MRI. *J Neuroimaging.* 2001;11:55–59.
18. Kaiboriboon K, Cortese C, Hogan RE. Magnetic resonance and positron emission tomography changes during the clinical progression of Rasmussen encephalitis. *J Neuroimaging.* 2000;10:122–125.
19. Fakhoury T, Abou-Khalil B, Kessler RM. Limbic encephalitis and hyperactive foci on PET scan. *Seizure.* 1999;8:427–431.
20. Hirayama K, Sakazaki H, Murakami S, et al. Sequential MRI, SPECT and PET in respiratory syncytial virus encephalitis. *Pediatr Radiol.* 1999;29:282–286.
21. Casse R, Rowe CC, Newton M, et al. Positron emission tomography and epilepsy. *Mol Imaging Biol.* 2002;4:338–351.
22. Theodore WH, Brooks R, Sato S, et al. The role of positron emission tomography in the evaluation of seizure disorders. *Ann Neurol.* 1984;15(suppl):S176–S179.
23. Theodore WH. The role of fluorodeoxyglucose-positron emission tomography in the evaluation of seizure disorders. *Semin Neurol.* 1989;9:301–306.
24. Handforth A, Cheng JT, Mandelkern MA, et al. Markedly increased mesiotemporal lobe metabolism in a case with PLEDs: further evidence that PLEDs are a manifestation of partial status epilepticus. *Epilepsia.* 1994;35:876–881.