


Provided for non-commercial research and educational use.
Not for reproduction, distribution or commercial use.

This article was originally published in the *Encyclopedia of Neuroscience* published by Elsevier, and the attached copy is provided by Elsevier for the author's benefit and for the benefit of the author's institution, for non-commercial research and educational use including without limitation use in instruction at your institution, sending it to specific colleagues who you know, and providing a copy to your institution's administrator.



All other uses, reproduction and distribution, including without limitation commercial reprints, selling or licensing copies or access, or posting on open internet sites, your personal or institution's website or repository, are prohibited. For exceptions, permission may be sought for such use through Elsevier's permissions site at:

<http://www.elsevier.com/locate/permissionusematerial>

Newberg A B and Alavi A (2009) Single Photon Emission Computed Tomography (SPECT): Technique. In: Squire LR (ed.) *Encyclopedia of Neuroscience*, volume 8, pp. 871-880. Oxford: Academic Press.

Single Photon Emission Computed Tomography (SPECT): Technique

A B Newberg and A Alavi, University of Pennsylvania, Philadelphia, PA, USA

© 2009 Elsevier Ltd. All rights reserved.

Introduction

Single photon emission computed tomography (SPECT) was developed in the 1960s and was used to obtain the first transaxial reconstructions of radionuclide distribution in the brain. This technique was used to study a number of neurological and psychiatric disorders and the impact of these disorders on radionuclide distribution in the central nervous system (CNS). SPECT was the first functional imaging modality that was used in the study of the CNS, and these early studies met with much success. The SPECT studies employed single-photon emitters such as iodine-123 (^{123}I) or technetium-99m ($^{99\text{m}}\text{Tc}$) as the radionuclide that was attached to the substrate. The most commonly used clinical radioligands for SPECT are $^{99\text{m}}\text{Tc}$ hexamethyl propylene amine oxime (HMPAO) and technetium-99m bisate to measure blood flow. However, a number of radiopharmaceuticals (see Table 1) for SPECT imaging have been developed to study various aspects of cerebral function, including a wide array of neurotransmitters. The radiopharmaceuticals used with SPECT imaging has been widely used in the evaluation of patients with various neurological and psychiatric disorders as well as various activation states of the brain.

SPECT imaging is highly advantageous for a number of reasons, comparing favorably with other imaging modalities such as functional magnetic resonance imaging (fMRI) and positron emission tomography (PET). Several noteworthy points about SPECT imaging include:

- *In vivo* imaging techniques allow the study of humans over extended periods of time. These longitudinal studies provide valuable information and may be particularly important in studies of the progression of disease and the response to treatment.
- The SPECT system, using the fan beam collimator, has good sensitivity and excellent spatial resolution (although not typically as good as PET or fMRI).
- The single-photon tracers, especially $^{99\text{m}}\text{Tc}$ - and ^{123}I -labeled agents, are readily available at a relatively low cost.
- The tracers can be readily prepared from premade kits without the need for an on-site cyclotron.

- There is little or no possibility of saturating cerebral binding sites with the SPECT tracers because the specific activity of these tracers is very high, $>100\,000\text{ Ci mmol}^{-1}$. The chemical amount to be injected in humans is too small to affect the number of available binding sites in the brain. Such tracers do not result in any measurable pharmacological effects.
- The localization and density of specific binding sites or biological processes in their native states can be investigated. The kinetic information determined by SPECT imaging can only be obtained by such techniques.

Normal Variants in SPECT Imaging

The ability to detect abnormalities on clinical brain SPECT scans or in research studies initially requires a determination of the normal variations that might be observed on such scans. One of the primary issues related to the definition of normal that arises with brain imaging is the determination of the baseline brain state (Figure 1). There has been considerable attention in the literature regarding the best conditions for obtaining a baseline functional imaging study. What the patient is doing and experiencing may have a profound influence on brain function. This has provided a foundation for activation studies that are typically performed on healthy individuals involved in various sensorimotor, cognitive, or affective tasks. For example, the brain function with eyes open is markedly different than the brain with the eyes closed. Once the eyes are open, there is a dramatic increase in the primary visual areas. This activity increases with the complexity of the scene being presented to the brain and may also include other association areas. Movement in the external environment also alters function in the visual centers of the brain as well as in the medial prefrontal cortex, temporoparietal junction, basal temporal regions, and extrastriate cortex. Sounds also elicit changes in cerebral function and, therefore, whether the ears are occluded may influence brain function.

Technical factors must also be considered when evaluating brain function because they may introduce artifacts and findings that are, in reality, variants of normal brain perfusion. These include the time between injection and scanning, the dose administered, filtering and processing steps, test-retest variability, and the type of scanner. As the duration of time from the injection increases, it is possible that

Table 1 Partial list of existing SPECT tracers^a

Compound	Application
HMPAO, bismate	Cerebral blood flow
IQNB	Muscarinic cholinergic receptor
Iodopride, IBZM, iodospiperone	Dopamine receptor
AMIK, DOI	Serotonin receptor
TRODAT	Dopamine transporter
ADAM	Serotonin transporter
β -CIT	Dopamine or serotonin transporter
Iomazenil	Benzodiazepine
2-Iodomorphine	Opioid receptor
¹²³ I-d(CH ₂) ₅ [Tyr(Me) ₂ , Tyr(NH ₂) ₉]AV	Vasopressin receptor

^a β -CIT, [¹²³I]-2 β -carbomethoxy-3 β -(4-iodophenyl)-tropane; ADAM, 2-((2-((dimethylamino)methyl) phenyl)thio)-5-iodophenylamine; AMIK, 7-amino-8-iodo-ketanserin; DOI, 1-(2,5-dimethoxy-4-iodophenyl)-2-aminopropane; HMPAO, technetium-99m hexamethyl propylene amine oxime; IBZM, 3-iodo-N-[(1-ethyl-2-pyrrolidinyl)] methyl-2-hydroxy-6-methoxybenzamide; IMP, iodine-123-N-N', N,-trimethyl-N'-[2-hydroxyl-3-methyl-5-iodo-benzyl]-1, 3 propane diamine; IQNB, 3-quinuclidinyl benzilate; TRODAT, Tc-99m [2-[[[3-(4-chlorophenyl)-8-methyl-8-azabicyclo[3.2.1]oct-2-yl]-methyl](2-mercaptoethyl) amino]ethyl]amino]ethane-thiolato(3-)-N₂, N₂', S₂, S₂']oxo-[1R-(exo-exo)].

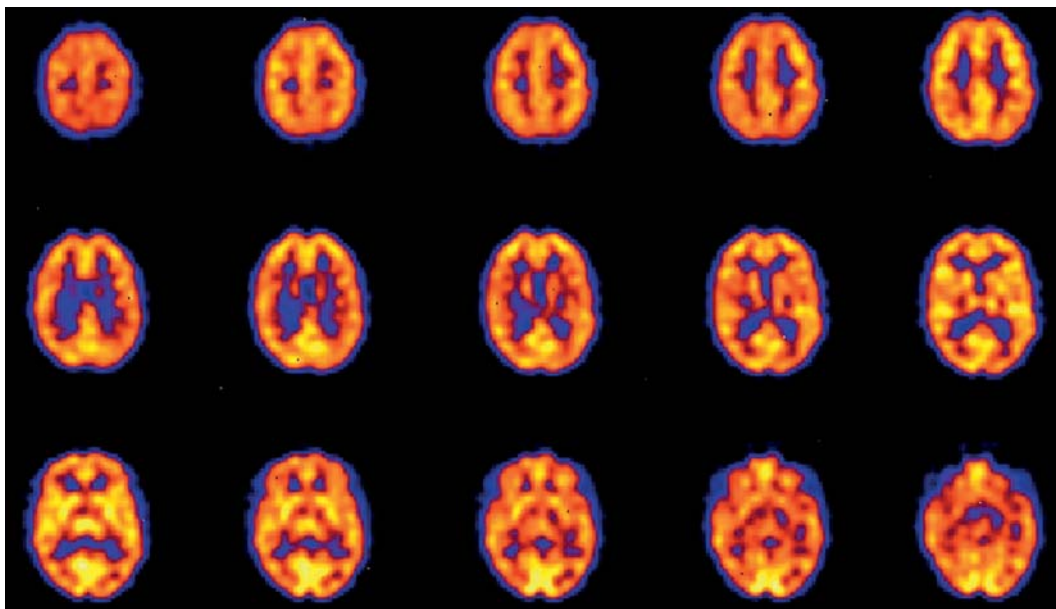


Figure 1 SPECT scan using ^{99m}Tc bismate showing uniform distribution of blood flow throughout the cortical and subcortical structures in a healthy subject. The images are axial slices from the top of the head to the cerebellum.

certain tracers may have an altered cerebral distribution. Obviously, the ideal tracer would remain completely fixed within the brain at the time of extraction from the blood. However, most tracers do experience some degree of washout and some even undergo redistribution. ^{99m}Tc bismate, for example, begins to wash out of the cortical regions faster than the subcortical areas. The result is that a scan obtained several hours after injection might appear to have pathologically low activity in the cortex compared to a scan of the same person obtained within the first hour of the injection. Other tracers,

especially neurotransmitters, may have altered bio-distribution over time, and this is a factor that must be considered for any clinical or research study.

Filtering and processing of the images is also crucial to determining cerebral activity. SPECT imaging with fan beam collimators and the appropriate application of filters is necessary to adequately visualize subcortical structures and central cortical areas (Figure 2). Attenuation correction is also necessary for adequately visualizing and comparing activity in various structures (Figure 3). Patient motion can always complicate interpretation of SPECT scans. Methods for

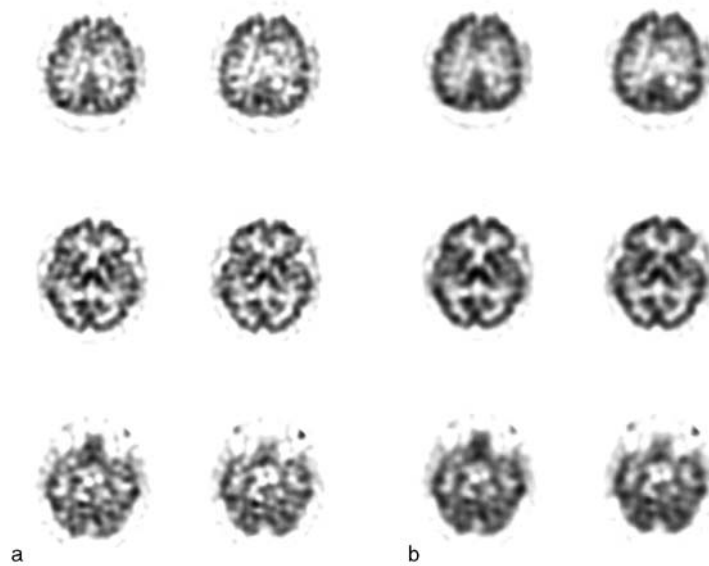


Figure 2 Transaxial SPECT images of ^{99m}Tc bicasate showing the differences in scans when processed via different Weiner filter multipliers of: (a) 0.3; (b) 0.6. In (a), the scan appears very grainy, making some structures difficult to observe. In (b), the scan appears to be much smoother, but there is less delineation between structures.

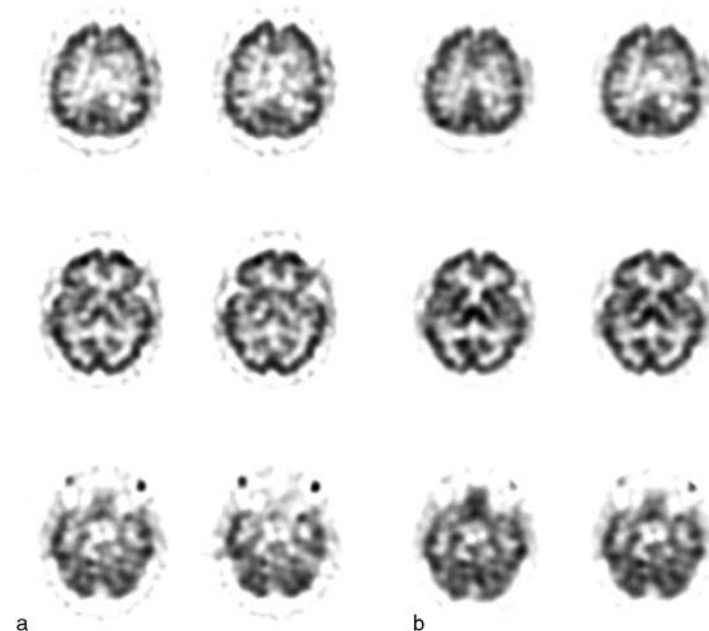


Figure 3 Transaxial SPECT images of ^{99m}Tc bicasate: (a) before correction for photon attenuation; (b) after correction for photon attenuation. The ability to restore counts to central structures results in much better observation of the subcortical structures, such as the thalamus, after attenuation correction is applied.

preventing patient motion from interfering with scanning include firm head holders and the use of tape or some other method to hold the head in place. Also, shortening image acquisition makes the session easier on the patient. Alternatively, breaking up the acquisition time into multiple shorter scans can be useful because scans with motion can be excluded without

losing the entire study. Another processing factor that can affect the visual inspection of brain scans is head tilt. Because a patient's head is rarely in complete alignment with the camera, slight and especially significant head tilt might result in certain areas appearing asymmetric in comparison to the contralateral structure. For example, the thalami can frequently

appear to have asymmetric activity if there is head tilt. However, this can usually be identified by examining all the slices containing the structure. As the slices proceed through the structure, asymmetries associated with head tilt should flip from one side to the other. This can usually be corrected by computer programs that realign brain images.

In spite of many of these issues, most studies of cerebral blood flow, metabolism, or even neurotransmitter systems have demonstrated good test–retest results with small variability within structures. Most studies have shown that in healthy controls repeat scans typically demonstrate regional activity and absolute activity to be within 5–10%.

SPECT Imaging from Infancy to Adulthood

The normal aging process is associated with a number of biochemical changes in the brain. Although post-mortem studies may help to elucidate the nature of these changes, the advent of functional neuroimaging techniques allowed these biochemical changes in the brain to be measured *in vivo* across the life span of the person.

During the first year of normal development, studies have shown that the pattern of activity observed on functional brain scans generally corresponds to the phylogenetic order of development. Thus, the functional maturation (as measured by increased metabolism) of developmentally older structures precedes that of structures that develop later. For example, as the visuospatial and visuosensorimotor function and primitive reflexes develop, increased cerebral function is observed in the parietal, temporal, cerebellar, and primary visual cortices. Increases have also been observed in the basal ganglia as movement and sensorimotor function becomes more integrated. Function in the frontal lobe remains low during the first 4 months of life and increases as the infant begins to develop higher cortical and cognitive capabilities. Thus, as the infant develops more complex social interactions as well as improves his or her abilities in various neuropsychological tests that specifically involve frontal lobe function, these changes are reflected by increases in frontal lobe activity. By 1 year of age, the overall pattern of activity is qualitatively similar to that of a young adult.

The results of studies in adults that have measured cerebral blood flow in normal aging have generally noted a global decrease in cerebral blood flow with age. This typically affects the gray matter more than the white matter. Furthermore, the decrease appears to be nonlinear, with a sharper decrease prior to the age of approximately 36 years followed by a slower decline. Several areas appear to be affected, but the

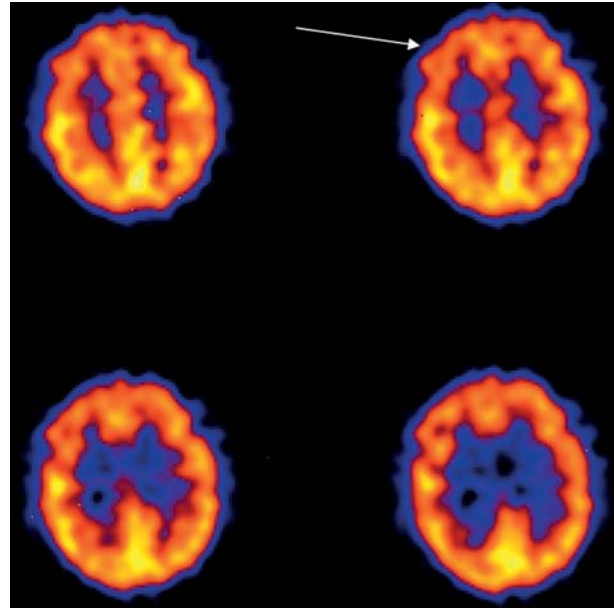


Figure 4 Transaxial SPECT images of ^{99m}Tc bismuth citrate in normal aging with decreased bilateral frontal lobe perfusion (arrow).

most commonly observed decrease is in the frontal lobes bilaterally (Figure 4). However, age-related decline in tracer uptake also occurs in the anterior cingulate gyrus, bilateral basal ganglia, left prefrontal, left lateral frontal, and left superior temporal and insular cortex.

Neurotransmitter Function in Aging

In addition to measuring changes in cerebral blood flow with age, SPECT can measure neurotransmitter activity, which may also change with age. A large number of neurotransmitter systems can be studied using SPECT (see Table 1). Many of these have been used to study the effects of aging.

The nigrostriatal dopaminergic pathways have been studied with SPECT imaging. This pathway is important with regard to extrapyramidal symptoms that occur in the elderly. This system also has particular significance in the study of Parkinson's disease (PD). *In vitro* studies have generally shown decreases in both pre- and postsynaptic receptor levels with age. Several SPECT studies have been performed with ligands that bind to postsynaptic receptors such as D1 and D2. Radioligands that can measure the dopamine transporter system, which removes dopamine from the neuronal synapse into the terminal for storage, have also been developed. One study, using the cocaine analogs such as ^{99m}Tc TRODAT-1 and 2- β -carbomethoxy-3- β -(4-iodophenyl)tropane (β -CIT), indicated an age-related decrease in dopamine transporters. ^{99m}Tc TRODAT-1, has demonstrated a nonlinear decrease

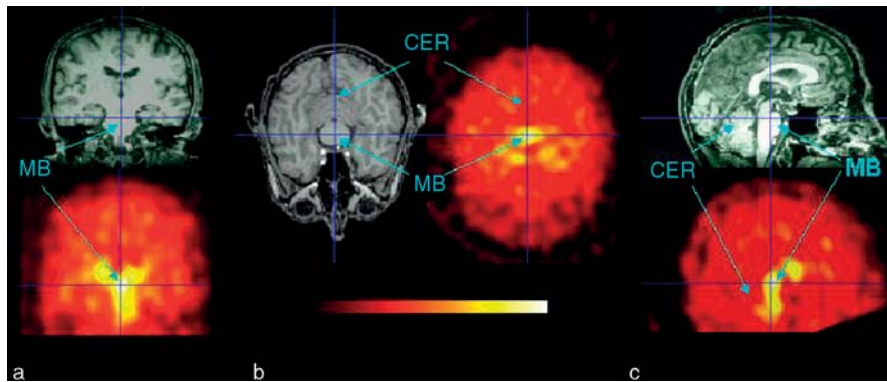


Figure 5 Multiple projections of ^{123}I ADAM SPECT and corresponding MRIs showing areas of substantial serotonin transporter binding in the midbrain with relatively little uptake in the cortex and cerebellum: (a) coronal; (b) transaxial; and (c) sagittal. CER, cerebellum; MB, midbrain.

in uptake with age. With this tracer, most of the decline appears to occur before the age of 40 years, with a slower decline from 40 to 75 years of age.

The serotonergic system is critical for a number of functions in the brain and is most notably involved in the regulation of mood. Several studies have examined the changes with age of the serotonin (5-HT) system using ^{123}I β -CIT or ^{123}I ADAM (Figure 5). Generally, there is a decline in binding to the 5-HT transporter of approximately 10% per decade in the thalamus and midbrain. An age-related decreased activity for the 5-HT_{1A} receptor has also been reported, with a decline of approximately 10% per decade in a number of cortical areas except for the medial temporal cortex. Similar decreases have been reported for the 5-HT_{2A} receptor.

Other neurotransmitter systems have not been widely studied with regard to the effects of aging. However, given the list of radioligands available for SPECT imaging, it seems that these techniques may have vast applications in the study of the neurotransmitter effects that result from normal aging as well as neurological and psychiatric disorders. Several studies have been mentioned, but there remains a significant amount of neurotransmitter systems which have yet to be thoroughly explored with regard to the effects of aging.

SPECT Imaging in Neuropsychiatric Disorders

Alzheimer's Disease

Since 1980, a large number of studies have used SPECT in the assessment of patients with Alzheimer's disease (AD). Most studies show that the bilateral parietal and temporal lobes are particularly affected in AD. This parietal hypoperfusion (Figure 6) is often referred to as representing the typical pattern of AD

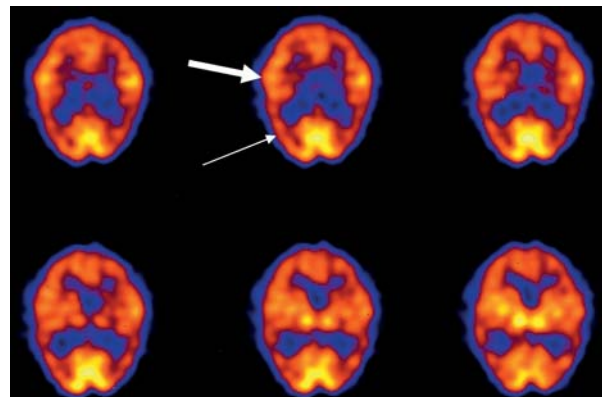


Figure 6 Transaxial SPECT images of $^{99\text{m}}\text{Tc}$ bicasate in a patient with late Alzheimer's disease (AD). There is moderately decreased perfusion in both temporoparietal regions (thin arrow) in comparison to the control studies shown in previous figures. In this later stage of AD, there is also decreased perfusion in the frontal lobes with preservation of perfusion only in the sensorimotor areas (thick arrow), visual cortex, and subcortical structures.

and may be particularly pronounced in patients younger than 65 years. However, it should be noted that, although the bilateral parietal pattern is highly predictive of AD, the pattern is not pathognomonic for AD and may be seen in patients with PD, bilateral parietal subdural hematomas, bilateral parietal stroke, and bilateral parietal radiation therapy ports. In spite of this limitation, until recently, SPECT has been widely used for assisting in the diagnosis of AD. More recently, fluoro-2-deoxyglucose (FDG) PET has been used for the diagnosis of AD and frontal lobe dementia. Given the superior image quality of FDG PET, this may ultimately replace the use of SPECT in the workup of patients with memory problems.

In patients with AD of varying severity, the magnitude and extent of hypoperfusion correlate with the severity of the dementia symptoms. Other areas (the sensorimotor and visual cortices, subcortical nuclei,

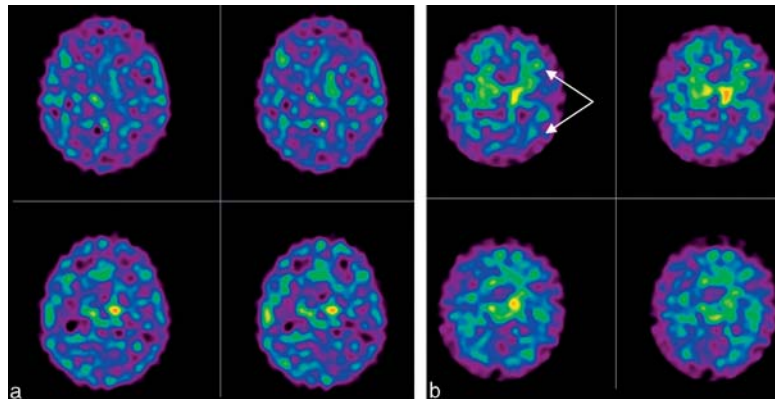


Figure 7 Transaxial SPECT images of ^{123}I IMPY: (a) in an elderly control subject; (b) in a patient with Alzheimer's disease (AD). There is substantially greater binding in the cortex in the AD patient than in the control (arrows).

brain stem, and cerebellum) have relatively preserved perfusion except in patients with specific neuropsychological deficits.

Newer SPECT radiopharmaceuticals are being developed to specifically target the pathophysiological process of AD. For example, ^{123}I IMPY, which binds to the amyloid protein, has recently been developed and tested in human subjects (Figure 7). It is hoped that such compounds will be useful for early diagnosis as well as monitoring responses to interventions designed to attenuate the pathophysiological process.

Cerebrovascular Disease

Cerebrovascular disease is the third leading cause of death in the United States and affects approximately half a million people. However, stroke is often associated with a poor outcome, in part due to the lack of understanding of the mechanisms that underlie stroke and the process by which recovery may take place. SPECT, in addition to PET, imaging has been of great benefit in advancing the understanding of the pathophysiology of cerebrovascular disorders. SPECT imaging allows for the detection of stroke earlier and with higher sensitivity than anatomic imaging with either MRI or computed tomography (CT). Further, SPECT imaging has been useful in evaluating the extent of the functional damage because areas not immediately affected by the infarct may show hypoperfusion (Figure 8). However, SPECT studies have not become prominent in the management of stroke patients for several reasons. One of the most important initial issues is whether a stroke is hemorrhagic, and SPECT cannot make this determination. Further, SPECT has not been shown to substantially alter management in the acute setting. In the chronic setting, SPECT may help with prognosis and to predict

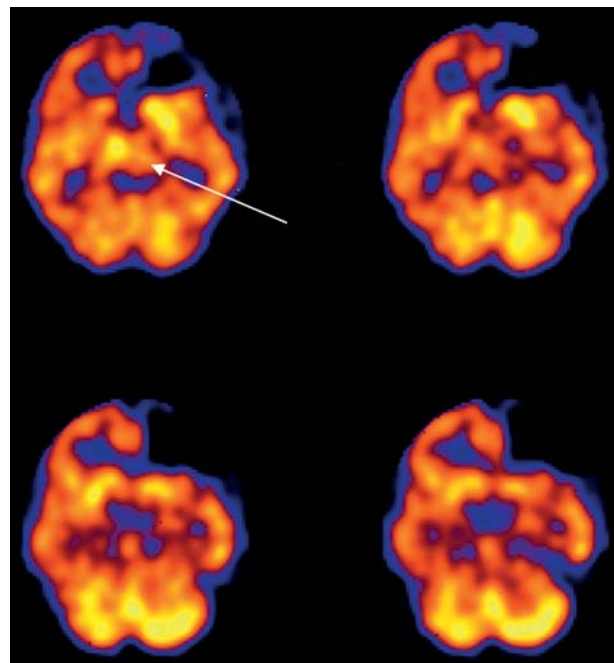


Figure 8 Transaxial SPECT images of $^{99\text{m}}\text{Tc}$ bicisate in a patient with recent left frontal lobe stroke. The scan shows near-absent activity in the left frontal region. There is also decreased perfusion in the ipsilateral thalamus (arrow), which may be associated with deafferentation from the affected regions in the left frontal lobe.

functional recovery, but this is not often useful in the clinical setting.

Where SPECT has been helpful is in the evaluation of cerebrovascular reserve, patients are given an initial SPECT scan followed by a second scan in which they have been pretreated with acetazolamide. Acetazolamide causes cerebral vasodilation, which unmasks areas that are at risk for future ischemic events. This helps to guide possible surgical interventions such as carotid endarterectomy.

Head Trauma

There have been a limited number of studies using SPECT in the evaluation of patients with head trauma. One of the problems with the use of SPECT in these cases is that SPECT cannot distinguish between structural damage and cerebral dysfunction because these may all result in areas of decreased perfusion. Thus, it is helpful to compare SPECT to anatomic images such as those obtained by MRI or CT, especially because cerebral dysfunction can extend beyond the boundary of anatomic lesions and may appear even in locations remote from the trauma.

Lesions such as cortical contusions, intracranial hematoma, and resultant encephalomalacia have perfusion defects that are confined primarily to the site of injury. However, subdural and epidural hematomas often cause widespread hypoperfusion and may affect even the contralateral hemisphere. Another entity, diffuse axonal injury, has been found to cause diffuse cortical hypoperfusion, but there is a particularly marked decrease in metabolism in the thalamus which appears to correlate with the severity of cognitive

dysfunction. Further, crossed cerebellar diaschisis, as well as ipsilateral cerebellar hypoperfusion, has been found in head-injury patients with supratentorial lesions.

Seizures

Epilepsy affects 0.5–1.0% of the population, can cause focal or generalized seizures, and usually begins in childhood. In general, during an epileptic seizure, cerebral metabolism and blood flow are markedly increased. The focus of partial seizures can be identified using SPECT imaging because these areas have increased blood flow during the seizure and decreased blood flow in the interictal period (**Figure 9**). It has been shown that single hypoperfused regions can be identified in up to 80% of patients with focal electroencephalogram (EEG) abnormalities. The degree of asymmetry in the region of the seizure focus appears greater with increasing duration of the seizure disorder. The type of seizure preceding the SPECT study may also affect the cerebral blood flow landscape such that hypoperfusion is limited to the epileptogenic zone if the preceding seizure is focal limbic,

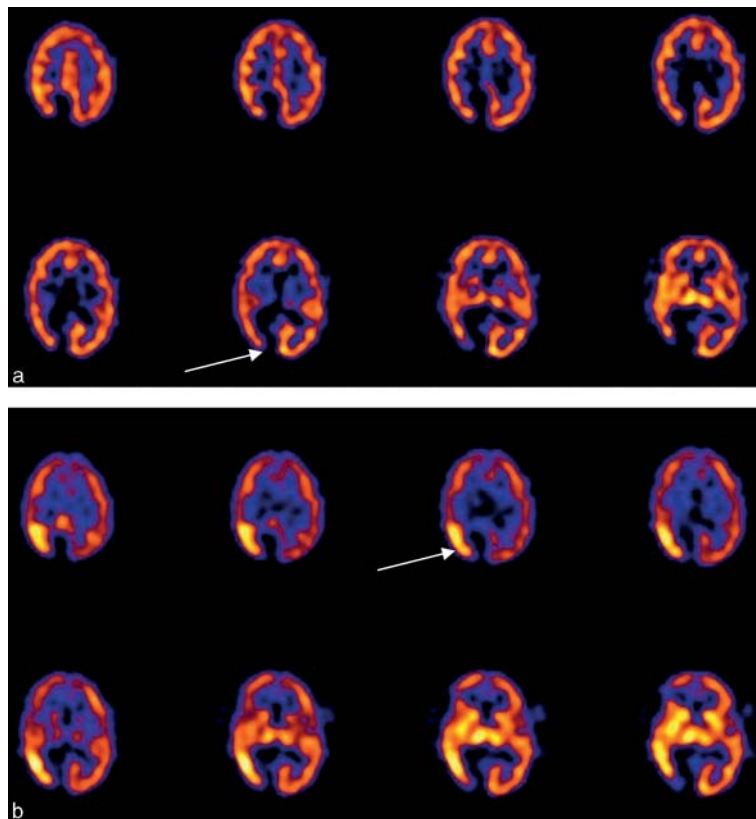


Figure 9 Transaxial SPECT images of ^{99m}Tc bismuth citrate in a patient with seizures: (a) interictal scan; (b) ictal scan. The interictal scan in (a) shows decreased activity in the region of prior surgery with mildly decreased activity in the adjacent cortex (thin arrow). The ictal scan in (b) shows the surgical area as decreased perfusion, but there is an intense focus of activity in the adjacent cortex (thin arrow), clearly delineating the seizure focus.

whereas patients with widespread limbic seizures have hypoperfusion that includes one or several additional areas of the limbic cortex.

The temporal lobe is the most common focus of partial epilepsy (Figure 9). Studies show that the sensitivity of interictal SPECT in detecting temporal lobe epilepsy (TLE) foci is over 70%. Ictal SPECT studies provide a more sensitive evaluation of seizure foci and can detect areas of hyperperfusion in up to 80% of patients. When statistical parametric mapping or coregistration with MRI is used to enhance detection, the sensitivity can be improved up to 90%. When additional cerebral areas of abnormality are detected, the implication is that the seizures have a more complex origin. This also makes surgical excision of the seizure focus, an important intervention in patients refractory to medications, less likely to be successful.

Depression

Depression is generally characterized by decreased cortical perfusion, particularly affecting the frontal lobes (Figure 10). However, the exact pattern has been somewhat controversial, with different studies reporting slightly discrepant findings. Furthermore, generalized decreases in cortical perfusion have also been reported with a number of psychotropic medications such as benzodiazepines, sedatives, antipsychotic medications, and anticonvulsant medications. Thus, SPECT cerebral blood flow imaging of depression has generally not been very useful in a clinical or research setting.

A number of functional neuroimaging studies have focused on the role of the 5-HT system in depression,

including both pre- and postsynaptic receptors. 5-HT_{2A} postsynaptic receptors are generally reduced in the frontal cortex. SPECT studies of the 5-HT transporter using ¹²³I-β-CIT and ¹²³I-2-((dimethylamino)methyl)phenylthio)-5-iodophenylamine (ADAM) revealed reductions in binding in the brain stem in drug-free depressed patients compared to controls. Several initial SPECT studies of treatment effects suggested that antidepressant medication and also psychotherapy improve 5-HT function in patients who demonstrate a good response.

Movement Disorders

Parkinsonian symptoms are associated with a number of neurodegenerative disorders, such as PD, multiple system atrophy (MSA), and progressive supranuclear palsy (PSP). These disorders are frequently associated with abnormalities in a number neurophysiological processes. In particular, pathological evidence has shown that these disorders are associated with a loss of neurons, particularly in the nigrostriatal dopaminergic pathway.

SPECT and PET have become important tools in the differential diagnosis of these diseases and may have sufficient sensitivity to detect neuronal changes before the onset of clinical symptoms. Imaging is now being used to elucidate the genetic contribution to PD and, in longitudinal studies, to assess the efficacy and mode of action of therapeutic interventions such as neuroprotective drugs and surgery.

SPECT studies of radiotracer binding to postsynaptic dopamine receptors and presynaptic dopamine

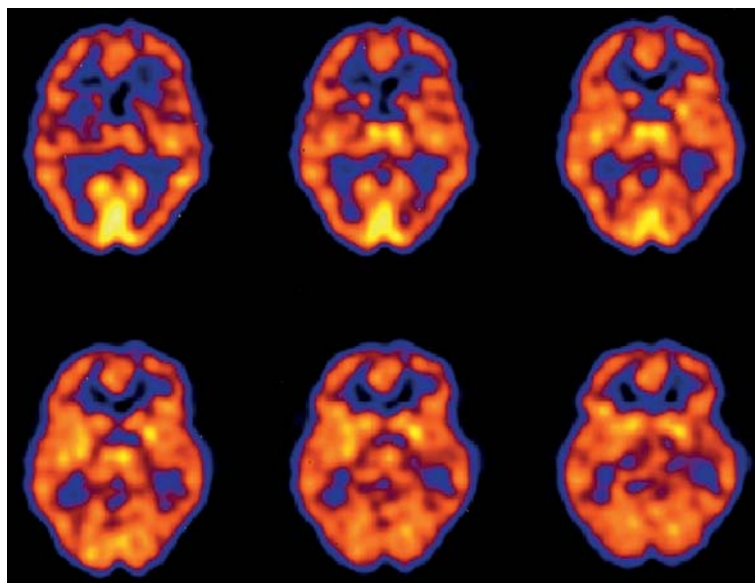


Figure 10 Transaxial SPECT images of ^{99m}Tc bicusate in a patient with depression show overall decreased perfusion in the cortex, with the frontal lobes most prominently affected. There is preserved perfusion in the visual cortex and thalamus.

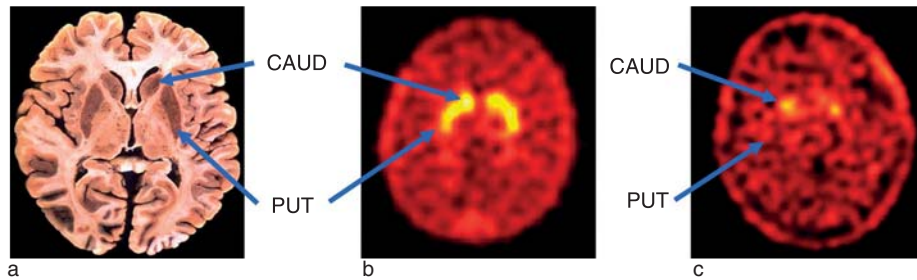


Figure 11 Transverse SPECT images of [^{99m}Tc]TRODAT-1 binding to dopamine transporters in human subjects: (a) histology slice through the brain at the level of the striatum showing the head of the caudate nucleus (CAUD) and the putamen (PUT); (b) image at the same level from a healthy subject showing high concentrations of [^{99m}Tc]TRODAT-1 binding to dopamine transporters in the caudate and putamen; (c) image at the same level in a patient with bilateral Parkinson's disease showing significant reductions of [^{99m}Tc]TRODAT-1 binding in the putamen but with the caudate relatively spared.

transporters and neurons have proved to be powerful techniques for quantifying the loss of dopaminergic neurons in normal aging and in PD and other neurodegenerative disorders. SPECT studies have indicated a consistent pattern of dopaminergic neuronal loss in PD, usually with a more pronounced decrease in the putamen rather than in the caudate (Figure 11). In addition, there is often a marked asymmetry of uptake in the striatum, particularly in the early stages of the disease. This asymmetry usually has a good correlation with symptom severity and illness duration. Most important, SPECT imaging studies may be sensitive enough to detect very early PD, perhaps even before clinical symptoms become apparent.

Although most of the SPECT studies have shown highly significant differences between groups of PD patients and age-matched normal controls, the statistically significant differential diagnosis of an individual subject is more problematic. Patients with severe PD are easily separated from healthy controls just from a simple visual inspection of striatal images, which can be quantified using some form of discriminant analysis which has a sensitivity and specificity from 90% to 100% in the proper clinical setting. However, patients presenting much earlier in the course of the disease are more difficult to detect because there can be a substantial overlap with an age-matched control group and, consequently, a loss of diagnostic accuracy. The situation may be further complicated if the early differential diagnosis among several different neurodegenerative disorders is required. Many of the symptoms associated with parkinsonian disorders are nonspecific, which is why the accurate clinical diagnosis of these diseases is difficult. Indeed, some histopathological studies have shown that as many as 25% of all patients who were diagnosed with PD before death had been misdiagnosed. Studies measuring dopamine transporter activity have had more difficulty in separating PD from MSA or PSP. Essential

tremor (ET) is another possible diagnosis to consider when evaluating a patient for PD. ET may be easier to distinguish from PD because the former does not typically involve the dopaminergic pathways to the same degree.

Conclusion

Functional imaging using SPECT has provided detailed *in vivo* measurements of cerebral biochemical activity that occur in the normal brain and various neuropsychiatric conditions. The ability to interpret findings depends both on technical issues that may affect the normal pattern of activity and on normal age-related changes. Changes with aging and various neuropsychiatric conditions can be reflected in cerebral blood flow and neurotransmitter concentrations. Overall, SPECT imaging will probably continue to play an important role in the evaluation of brain function in both the clinical and research setting.

See also: Aging of the Brain and Alzheimer's Disease; Alzheimer's Disease: An Overview; Alzheimer's Disease: MRI Studies; Cognition: An Overview of Neuroimaging Techniques; Depression and the Brain; Map Plasticity and Recovery from Stroke; Neuroimaging; Single Photon Emission Computed Tomography (SPECT); Stroke; Stroke: Neonate vs. Adult; Two-Photon Imaging.

Further Reading

- Alavi A and Hirsch LJ (1991) Studies of central nervous system disorders with single photon emission computed tomography and positron emission tomography: Evolution over the past 2 decades. *Seminars in Nuclear Medicine* 21: 58–81.
- Booij J, Habraken JB, Bergmans P, et al. (1998) Imaging of dopamine transporters with iodine-123-FP-CIT SPECT in healthy controls and patients with Parkinson's disease. *Journal of Nuclear Medicine* 39: 1879–1884.
- Camargo EE (2001) Brain SPECT in neurology and psychiatry. *Journal of Nuclear Medicine* 42: 611–623.

- Chugani HT (1992) Functional brain imaging in pediatrics. *Pediatric Clinics of North America* 39: 777–799.
- Diksic M and Reba RC (eds.) (1991) *Radiopharmaceuticals and Brain Pathology Studied with PET and SPECT*. Boca Raton, FL: CRC Press.
- Goodwin GM (1996) Functional imaging, affective disorder and dementia. *British Medical Bulletin* 52: 495–512.
- Kung HF (1991) Overview of radiopharmaceuticals for diagnosis of central nervous disorders. *Critical Review in Clinical Laboratory Science* 28: 269–286.
- Masdeu JC, Zubieta JL, and Arbizu J (2005) Neuroimaging as a marker of the onset and progression of Alzheimer's disease. *Journal of Neurological Sciences* 236: 55–64.
- Masterman DL, Mendez MF, Fairbanks LA, and Cummings JL (1997) Sensitivity, specificity, and positive predictive value of technetium 99m-HMPAO SPECT in discriminating Alzheimer's disease from other dementias. *Journal of Geriatric Psychiatry and Neurology* 10: 15–21.
- Mozley PD, Acton PD, Barraclough ED, et al. (1999) Effects of age on dopamine transporters in healthy humans. *Journal of Nuclear Medicine* 40: 1812–1817.
- Mozley PD, Sadek AM, Alavi A, et al. (1997) Effects of aging on the cerebral distribution of technetium-99m hexamethylpropylene amine oxime in healthy humans. *European Journal of Nuclear Medicine* 24: 754–761.
- Newberg AB, Alavi A, and Payer F (1995) Single photon emission computed tomography in Alzheimer's disease and related disorders. *Neuroimaging Clinics of North America* 5: 103–123.
- Pagani M, Salmaso D, Jonsson C, et al. (2002) Regional cerebral blood flow as assessed by principal component analysis and (99m)Tc-HMPAO SPECT in healthy subjects at rest: Normal distribution and effect of age and gender. *European Journal of Nuclear Medicine and Molecular Imaging* 29: 67–75.
- Pirker W, Asenbaum S, Bencsits G, et al. (2000) [¹²³I] β-CIT SPECT in multiple system atrophy, progressive supranuclear palsy, and corticobasal degeneration. *Movement Disorders* 15: 1158–1167.
- Van Heertum RL and Tikofsky RS (2000) *Functional Cerebral SPECT and PET Imaging*. Philadelphia: Lippincott Williams & Wilkins.
- Van Paesschen W (2004) Ictal SPECT. *Epilepsia* 45(supplement 4): 35–40.
- Wang J, Jiang YP, Liu XD, et al. (2005) 99mTc-TRODAT-1 SPECT study in early Parkinson's disease and essential tremor. *Acta Neurologica Scandinavica* 112: 380–385.
- Weng YH, Yen TC, Chen MC, et al. (2004) Sensitivity and specificity of ^{99m}Tc-TRODAT-1 SPECT imaging in differentiating patients with idiopathic Parkinson's disease from healthy subjects. *Journal of Nuclear Medicine* 45: 393–401.